

Noninvasive Follicular Thyroid Neoplasms with Papillary-like Nuclear Features and Indeterminate Cytology Are Afirma GEC Suspicious Which Facilitates Surgical Treatment

Peter M Sadow, MD, PhD,^{1,3} Virginia Anne LiVolsi, MD,² Gregory W Randolph, MD,³ Richard Mack Harrell, MD,⁴ Richard T Kloos, MD,⁵ and Ronald A Ghossein, MD⁶

(1) Dept. of Pathology, Massachusetts General Hospital and Harvard Medical School (2) Perelman School of Medicine of the University of Pennsylvania

(3) Massachusetts Eye and Ear Infirmary, Dept. of Otolaryngology Harvard Medical School, Boston MA

(4) Center for Integrative Endocrine Surgery, Memorial Healthcare System, Hollywood, FL

(5) Medical Affairs, Veracyte, Inc., South San Francisco, CA (6) Pathology, Memorial Sloan Kettering Cancer Center, New York, NY

Veracyte Consultants: Sadow, LiVolsi, Ghossein; Veracyte Employee: Kloos

BACKGROUND

The histopathological diagnosis of noninvasive follicular thyroid neoplasm with papillary-like nuclear features (NIFTP) is a nomenclature revision of the noninvasive encapsulated follicular variant of papillary thyroid carcinoma (PTC). Management recommendations currently suggest the surgical resection of NIFTP for diagnostic purposes. When evaluated by Thyroseq v2.1, 78% were mutation positive.¹ While the Afirma® Gene Expression Classifier was trained to render a suspicious result in all variants of PTC, whether or not most NIFTP yield GEC Suspicious results is unknown. This is important as NIFTP may represent 19% of what is currently defined as PTC, and could affect over 45,000 patients worldwide each year.¹

METHODS

The ENHANCE biorepository contains samples with paired cytologic, genomic and histopathological labels. The histologic labels are assigned by a panel of expert pathologists masked to the genomic data and cytological and histological diagnoses. For this study we queried the biorepository for nodules histologically diagnosed as NIFTP by the expert panel and evaluated their corresponding ultrasound characteristics, cytology diagnoses and GEC results.

REFERENCES

1. Nikiforov YE, et al. *JAMA Oncol.* 2016

RESULTS

Twenty-five biopsied nodules were histologically diagnosed as NIFTP by the expert panel. Their preoperative FNA cytology according to the Bethesda System was 15 B-III, 9 B-IV, and 1 B-V with no differences observed between those read by Thyroid Cytopathology Partners vs. elsewhere (Chi-Square P=0.4). Mean patient age was 53.6 years (range 26-82), and mean nodule size was 2.8 cm (range 1.2-6.6) (See Table 1). Among those with various nodule US characteristics reported by the enrolling physician, 100% were solid or predominantly solid. Echogenicity was hypoechoic 47%, isoechoic 40%, and hyperechoic 13%. 100% had a well-defined margin, 23 of 25 lacked microcalcifications, 24 of 25 were not taller-than-wide, and 100% lacked rim calcifications with small extrusive soft tissue component or extrathyroidal extension (See Figure 1). Overall, none had an ATA high suspicion sonographic pattern. The Afirma GEC was suspicious in 24 of 25 (96%) (See Figure 2). One 3 cm nodule with B-III cytology was Afirma GEC Benign and NIFTP. Its clinical and radiological characteristics were similar to the others.

CONCLUSION

None of the 25 NIFTP demonstrated an ATA high suspicion sonographic pattern, while 96% were Afirma GEC Suspicious. This high sensitivity molecular diagnosis aligns with current recommendations favoring surgical treatment of NIFTP (without total thyroidectomy or radioiodine ablation).

FIGURE 1.

No Biopsied Nodules Had an ATA High Suspicion Sonographic Pattern

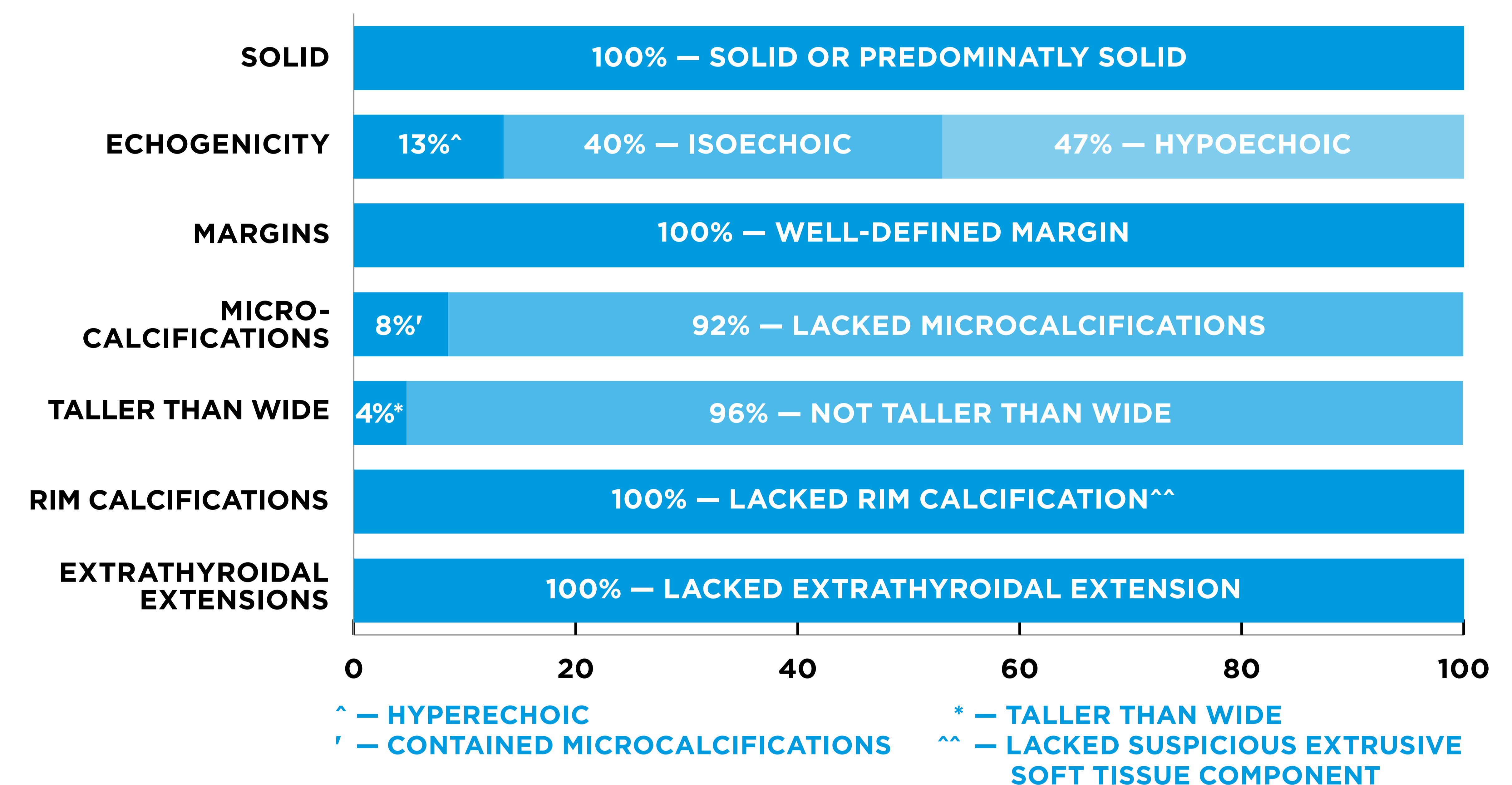


TABLE 1.

Patient and Nodule Demographics

Variable	Total NIFTP Samples
Patients	
Age — mean (range)	53.6 (26-82)
Gender	25
Male — no. (%)	7 (28%)
Female — no. (%)	18 (72%)
Thyroid Nodules	
Cytology	25
Bethesda III — no. (%)	15 (60%)
Bethesda IV — no. (%)	9 (36%)
Bethesda V — no. (%)	1 (4%)
Nodule size — mean (range)	2.8 cm (1.2-6.6 cm)

FIGURE 2.

Classification of NIFTP Samples by Afirma GEC

